



saving faces | changing lives®

American Association of Oral and Maxillofacial Surgeons

Position Paper



Medication-Related Osteonecrosis of the Jaw—2014 Update

Special Committee on Medication-Related Osteonecrosis of the Jaws:

Salvatore L. Ruggiero, DMD, MD, Clinical Professor, Division of Oral and Maxillofacial Surgery, Stony Brook School of Dental Medicine, Hofstra North Shore-LIJ School of Medicine, New York Center for Orthognathic and Maxillofacial Surgery, Lake Success, NY

Thomas B. Dodson, DMD, MPH, Professor and Chair, Associate Dean for Hospital Affairs, University of Washington School of Dentistry, Department of Oral and Maxillofacial Surgery, Seattle, WA

John Fantasia, DDS, Chief, Division of Oral Pathology, Hofstra North Shore-LIJ School of Medicine, New Hyde Park, NY

Reginald Goodday, Professor, Department of Oral and Maxillofacial Sciences, Dalhousie University, Halifax, NS

Tara Aghaloo DDS, MD, PhD, Associate Professor, Oral and Maxillofacial Surgery, Assistant Dean for Clinical Research, UCLA School of Dentistry, Los Angeles CA;

Bhoomi Mehrotra, MD, Director, Cancer Institute at St. Francis Hospital, Roslyn, NY

Felice O’Ryan, DDS, Division of Maxillofacial Surgery, Kaiser Permanente Oakland Medical Center, Oakland, CA

Introduction

To accommodate the growing number of osteonecrosis cases involving the maxilla and mandible associated with antiresorptive (denosumab) and antiangiogenic therapies, in addition to bisphosphonates, the Special Committee has recommended that the nomenclature of bisphosphonate-related osteonecrosis of the jaw be replaced with the term medication-related osteonecrosis of the jaw (MRONJ).

MRONJ adversely affects the quality of life, producing significant morbidity. Strategies for management of patients with, or at risk for, MRONJ were set forth in the American Association of Oral and Maxillofacial Surgeons (AAOMS) updated *Position Paper on Bisphosphonate-Related Osteonecrosis of the Jaws* and approved by the Board of Trustees in 2009.¹ The Position Paper was developed by a Special Committee appointed by the Board and composed of clinicians with extensive experience in caring for these patients and basic science researchers. The knowledge base and experience in addressing MRONJ has expanded, necessitating modifications and refinements to the previous *Position Paper*. This Special Committee re-convened once again in September 2013 to appraise the current literature and revise the guidelines as indicated in order to more accurately reflect the current knowledge in this field. This update contains revisions to diagnosis, staging, and management strategies, and highlights the status of current research. AAOMS considers it vitally important that this information be disseminated to other relevant health care professionals and organizations.

Purpose

The purpose of this updated position paper is to provide:

1. Perspectives on the risk of developing MRONJ and the risks and benefits of those medications related to osteonecrosis of the jaw (ONJ) in order to facilitate medical decision-making of both the treating physician, dentist, dental specialist, and patients;

2. Guidance to clinicians regarding the differential diagnosis of MRONJ in patients with a history of exposure to antiresorptive and/or antiangiogenic agents;
3. Guidance to clinicians on MRONJ prevention measures and management strategies for patients with MRONJ based on the disease stage.

Background

Antiresorptive medications

Intravenous (IV) bisphosphonates (BPs) are antiresorptive medications used to manage cancer-related conditions including hypercalcemia of malignancy, skeletal-related events (SRE) associated with bone metastases in the context of solid tumors such as breast cancer, prostate cancer and lung cancers, and for management of lytic lesions in the setting of multiple myeloma.²⁻¹³ While the potential for bisphosphonates to improve cancer-specific survival remains controversial, these medications have had a significant positive effect on the quality of life for patients with advanced cancer involving the skeleton.

IV BPs, ie once yearly infusion of zoledronate (Reclast®) and a parenteral formulation of ibandronate (Boniva®) administered every three months, have FDA approval for management of osteoporosis.¹⁴

Oral bisphosphonates are approved for treatment of osteoporosis and are frequently used to treat osteopenia as well.¹⁵ They are also used for a variety of less common conditions such as Paget's disease of bone, and osteogenesis imperfecta.^{16,17} The most common use, however, is for osteoporosis.^{18,19}

RANK ligand inhibitor (denosumab) is an antiresorptive agent that exists as a fully humanized antibody against Rank ligand (RANK-L) and inhibits osteoclast function and associated bone resorption. When denosumab (Prolia®) is administered subcutaneously every 6 months there is a reduction in the risk of vertebral, non-vertebral, and hip fractures in osteoporotic patients.^{20,21} Denosumab (Xgeva®) is also effective in reducing SRE related to metastatic bone disease from solid tumors when administered monthly.^{22,23} Denosumab therapy is not indicated for the treatment of multiple myeloma. Interestingly, in contrast to bisphosphonates, RANK ligand inhibitors do not bind to bone and their effects on bone remodeling are mostly diminished within 6 months of treatment cessation.

Position Paper



Antiangiogenic medications

Angiogenesis inhibitors interfere with the formation of new blood vessels by binding to various signaling molecules disrupting the angiogenesis-signaling cascade. These novel medications have demonstrated efficacy in the treatment of gastrointestinal tumors, renal cell carcinomas, neuroendocrine tumors and others.

Risks of jaw necrosis related to antiresorptive therapy

Oral and maxillofacial surgeons first recognized and reported cases of non-healing exposed bone in the maxillofacial region in patients treated with IV bisphosphonates.^{24,25} In September 2004, Novartis, the manufacturer of the IV bisphosphonates pamidronate (Aredia®) and zoledronic acid (Zometa®), notified healthcare professionals of additions to the labeling of these products, which provided cautionary language related to the development of osteonecrosis of the jaws.²⁶ This was followed in 2005 by a broader drug class warning of this complication for all bisphosphonates including the oral preparations.^{27,28} More recently, other antiresorptive agents and novel anti-cancer drugs have been linked to the development of jaw necrosis (Appendix I, II).

MRONJ Case Definition

In order to distinguish MRONJ from other delayed healing conditions and address evolving clinical observations and concerns about under-reporting of disease, the working definition of MRONJ has been modified from the 2009 *AAOMS Position Paper*:¹

Patients may be considered to have MRONJ if all of the following characteristics are present:

1. Current or previous treatment with antiresorptive or antiangiogenic agents;
2. Exposed bone or bone that can be probed through an intraoral or extraoral fistula(e) in the maxillofacial region that has persisted for more than eight weeks; and
3. No history of radiation therapy to the jaws or obvious metastatic disease to the jaws.

It is important to understand that patients at risk for or with established MRONJ can also present with other common clinical conditions not to be confused with MRONJ. Commonly misdiagnosed conditions may include, but are not limited to: alveolar osteitis, sinusitis, gingivitis/periodontitis, caries, periapical pathology, fibro-osseous lesion, sarcoma, chronic sclerosing osteomyelitis, and TMJ disorders. It is also important to remember that ONJ occurs in patients not exposed to antiresorptive or antiangiogenic agents.

Pathophysiology

Although the first MRONJ case was reported over a decade ago, the pathophysiology of the disease has not been fully elucidated.^{24,25} A source of great debate among clinicians and researchers are the potential mechanisms underlying MRONJ pathophysiology.²⁹⁻³² Proposed hypotheses that attempt to explain the unique localization of MRONJ exclusively to the jaws include altered bone remodeling or oversuppression of bone resorption, angiogenesis inhibition, constant microtrauma, suppression of innate or acquired immunity, vitamin D deficiency, soft tissue BP toxicity, and inflammation or infection.^{29,33-40}

A. Inhibition of osteoclastic bone resorption and remodeling

Bisphosphonates (BP), and other antiresorptives such as denosumab, inhibit osteoclast differentiation and function, and increase apoptosis, all leading to decreased bone resorption and remodeling.⁴¹⁻⁴⁵ Osteoclast differentiation and function plays a vital role in bone healing and remodeling in all skeletal sites, but osteonecrosis of the jaws only occurs primarily within the alveolar bone of the maxilla and mandible.⁴⁶ An increased remodeling rate in the jaws may explain the differential predisposition to ONJ compared to other bones in the axial or appendicular skeleton. Long term studies in the large animal model demonstrate decreased intracortical bone turnover with dynamic histomorphometry.^{30,47} The central role of bone remodeling inhibition is further corroborated by a similar incidence of ONJ observed with other antiresorptive medications such as denosumab.⁴⁸⁻⁵⁰ Preliminary evidence exists demonstrating the improved extraction socket healing in animals receiving systemic zoledronic acid when treated with parathyroid hormone, possibly due to its positive effect on osteoclasts to increase bone remodeling.^{51,52}

Position Paper



B. Inflammation/Infection

Both systemic and local oral risk factors have been implicated in ONJ pathogenesis, where several human studies have implicated dental disease or bacterial infection.⁵³⁻⁵⁵ Although tooth extraction was performed in most of the initial reported cases of ONJ, these teeth commonly had existing periodontal or periapical disease.^{1,56-59} From these clinical studies, several animal models have been developed to demonstrate that both inflammation or bacterial infection and systemic antiresorptives are sufficient to induce ONJ.^{46,60-64}

Inflammation or infection has long been considered an important component of ONJ. Early studies identified bacteria, especially *Actinomyces* species, in biopsied specimens of necrotic bone removed in patients with ONJ.⁶⁵ The presence of bacteria has prompted studies to evaluate the possibility of a complex biofilm on exposed bone.⁶⁶ These studies have identified bacteria in combination with fungi and viruses, which may require more sophisticated therapies to combat the multiorganism ONJ-associated biofilm.⁶⁷⁻⁷⁰

C. Inhibition of Angiogenesis

Angiogenesis is a process that involves growth, migration and differentiation of endothelial cells to form new blood vessels. Angiogenesis favorably influences tumor growth and also influences tumor invasion of vessels, resulting in tumor metastasis. Angiogenesis requires binding of signaling molecules such as vascular endothelial growth factor (VEGF) to receptors on the endothelial cells. This signaling promotes new blood vessel growth.

Osteonecrosis is classically considered an interruption in vascular supply or avascular necrosis, and therefore, it is not surprising that inhibition of angiogenesis is a leading hypothesis in ONJ pathophysiology.^{30-32,71} In vitro experiments consistently demonstrate a reduction in angiogenesis in response to zoledronic acid.^{40,72} Studies in cancer patients treated with zoledronic acid support these data with decreased circulating VEGF levels.⁷³ Moreover, there is a growing body of literature linking osteonecrosis of the jaw and other bones in

patients receiving novel antiangiogenic drugs (tyrosine kinase inhibitors and monoclonal antibody targeting VEGF). However, inhibition of angiogenesis has not been reported with denosumab.

D. Other Hypotheses

1. Soft tissue toxicity

Although BPs primarily target the osteoclast and bind to hydroxyapatite in bone, soft tissue toxicity has been reported.^{29,74} Multiple cell types underwent increased apoptosis or decreased proliferation after exposure to BPs in vitro including cervical, prostate, and oral epithelial cells.⁷⁵⁻⁷⁷ Since BPs are excreted renally after only a few hours in the circulation, their concentration in tissues outside bone is minimal.⁷⁸ In contrast to BP's, no soft tissue toxicity has been reported with denosumab.

2. Innate or acquired immune dysfunction

The first animal model could not consistently induce ONJ unless BPs were combined with steroids in a tooth extraction defect.³⁷ Since then, many other studies showed mucosal ulceration, delayed healing, exposed bone, and histologic necrosis and inflammation when BPs and chemotherapy are administered in rodents undergoing extractions.^{34,63,79,80}

As described above, many hypotheses exist, and many of the animal models above show evidence that the disease may be multifactorial. To begin to develop effective therapies for patients with ONJ, clinically relevant animal models are paramount. Whether it is early diagnosis, prevention, or targeted therapy, therapeutic strategies cannot be developed or tested without these models. As more studies uncover the mechanisms, large animal models will be critical in closely replicating human MRONJ with frank bone exposure and stage 0 disease.

Risk factors for MRONJ

A. Medication-related risk factors

To interpret MRONJ disease frequency estimates, two parameters need to be considered: therapeutic indications and type of medications. The therapeutic indications are grouped into two categories: osteoporosis/osteopenia or malignancy. Medications will be grouped into two categories, BP and non-BP (other antiresorptive or antiangiogenic medications). Disease frequency will be reported as incidence (number of new cases

Position Paper

per sample [or population] per unit time) or prevalence (number of cases in the sample [or population] reported as a percentage).

Given the proliferation of data since MRONJ was originally reported in 2003, the committee has limited the inclusion of studies: 1) those published since the last report (2009), 2) studies with the highest levels of evidence for the available topic, eg systematic reviews of several randomized control trials (RCTs) or prospective cohort studies, individual RCTs, prospective cohort studies, retrospective cohort studies, or case-control studies, and 3) studies with clinical ascertainment of MRONJ. Older studies, case reports and case series, and studies that rely on medical record review or insurance-claim data were excluded from further analyses.

Due to the low frequency of disease, studies with small samples (<500 subjects) need to be interpreted cautiously. It is particularly challenging to obtain good estimates of disease frequency when studying low frequency events. Consistently, as the sample size increases, MRONJ disease frequency estimates get smaller. Therefore when reviewing the literature cited below, the reader should weight more heavily studies with large sample sizes than a comparable study with a smaller sample size (eg disease estimates of a study with a sample size of 10,000 should be weighted more heavily than a study with 500 subjects).

1. MRONJ risk among cancer patients

To measure the risk for ONJ among patients exposed to a medication, we must know the risk for ONJ in patients *not exposed* to antiresorptive or antiangiogenic medications. **The risk for ONJ among cancer patients enrolled in clinical trials and assigned to *placebo* groups ranges from 0% to 0.019% (0-1.9 cases per 10,000 cancer patients).**⁸¹⁻⁸³

Among cancer patients exposed to zoledronate, the cumulative incidence of MRONJ is in the low single digits (range = 0.7% - 6.7%).^{82,84} When limited to studies = those with Level 1 evidence, ie systematic reviews or RCTs, the risk of MRONJ in



subjects exposed to zoledronate approximates 1% (100 cases per 10,000 patients).^{81-83,85} **The risk of ONJ among cancer patients exposed to zoledronate ranges between 50-100 times higher than cancer patients treated with placebo.**

Among cancer patients exposed to denosumab, a RANK L inhibitor, the risk of MRONJ ranges from 0.7% - 1.9%.^{81,85} **This is similar to the risk of ONJ reported in patients exposed to zoledronate.**^{22,23,86}

The risk for ONJ among cancer patients exposed to bevacizumab, an antiangiogenic agent, is 0.2%. (20 cases per 10,000).⁸⁷ The risk may be higher among patients exposed to both bevacizumab and zoledronate, 0.9% (90 cases per 10,000).⁸⁷

There are also several reports describing jaw necrosis in cancer patients receiving targeted therapies, specifically tyrosine kinase inhibitors (TKIs) and monoclonal antibody targeting VEGF.⁸⁸⁻⁹⁰ In 2009 Brunello and colleagues reported consecutive episodes of ONJ, characterized by cutaneous fistula and bone sequestration, in a patient with renal cell carcinoma treated with bisphosphonates and the tyrosine kinase inhibitor (TKI) sunitinib.⁹¹ Disease improved after discontinuation of sunitinib and then rapidly worsened with resumption of sunitinib. The investigators hypothesized “that the antiangiogenic activity of sunitinib may amplify the inhibition of bone remodeling exerted by amino bisphosphonates entrapped within the osteonecrotic matrix, antagonize mucosal healing and expose to infections during treatment.” Subsequent reports have highlighted the potential additive toxic effect of antiangiogenic drugs (TKIs and monoclonal antibody targeting VEGF) in patients receiving or having a history of bisphosphonate medication use.^{87,92-98} Beuselink, et al, reported an overall incidence of ONJ to be 10% in renal cell carcinoma patients with bone metastasis treated with oral TKIs and concomitant bisphosphonates.⁹⁷ They concluded that the combined use of bisphosphonates and TKIs in renal cell carcinoma patients with bone involvement probably improves treatment efficacy but is associated with a high incidence of ONJ. Smidt-Hansen, et al, in a retrospective study of renal cell carcinoma patients who received zoledronic acid and sirolimus found that patients who developed ONJ had a significantly improved median survival of 31.6 months compared to 14.5 months in patients without ONJ.⁹⁸

Moreover, there have been multiple case reports detailing the development of ONJ in patients receiving these targeted antiangiogenic therapies who are bisphosphonate naïve.⁸⁸⁻⁹⁰ These case reports underscore the potential for novel medications such as TKIs and VEGF inhibitors being implicated in the development of ONJ in the absence of concomitant antiresorptive medication use.

This preliminary level of evidence supporting the association of antiangiogenic medications with the development of jaw necrosis is primarily based on case reports. While the FDA has issued an ONJ advisory only for bevacizumab and sunitinib,^{99,100} the committee remains concerned about a similar potential risk associated with several other medications within the same drug class which have a similar mechanism of action. Therefore, further controlled, prospective studies will be required to more fully characterize the risk of jaw necrosis associated with these agents.

2. MRONJ risk among osteoporosis patients

Most clinicians see patients exposed to antiresorptive therapy for management of osteoporosis. When evaluated by age, 5.1 million patients over the age of 55 years received a prescription for a bisphosphonate in year 2008. A recent federal study estimated that the prevalence of BP exposure was 7 for every 100 US population receiving a prescription for a bisphosphonate in the outpatient setting for the treatment of osteoporosis.¹⁰¹ Ironically, the studies estimating MRONJ risk in this patient population have the weakest levels of evidence of the various study groups, eg survey or retrospective cohort studies with ascertainment of disease based on a combination of examination or review of medical records.¹⁰¹

2a. Risk for ONJ among osteoporotic patients exposed to oral BPs

In a survey study of over 13, 000 Kaiser Permanente members, the prevalence of BRONJ in patients receiving long-term oral bisphosphonate therapy was reported at 0.1% (10 cases per 10,000) which



increased to 0.21 in patients with greater than 4 years of BP exposure.¹⁰² Felsenberg and Hoffmeister reported a prevalence of BRONJ among patients treated with bisphosphonates for osteoporosis of 0.00038% (<1 case per 100,000 exposed), based on reports of 3 cases to the German Central Registry of Necrosis of the Jaw.¹⁰³ In a more recent report, Malden, et al, derived an incidence of 0.004% (0.4 cases per 10,000 patient-years of exposure to alendronate) from 11 cases of MRONJ reported in a population of 90,000 people living in southeast Scotland.¹⁰⁴

2b. MRONJ risk among osteoporotic patients exposed to IV BP or RANK-L inhibitors

Studies analyzing patients with osteoporosis exposed to yearly zoledronate therapy for 3 years reported a risk for MRONJ of 0.017% (1.7 cases per 10,000 subjects).¹⁰⁵ An extension of this study through 6 years did not demonstrate change in frequency of MRONJ.¹⁰⁶ In recent reports studying patients exposed to denosumab, the risk for MRONJ is 0.04% (4 cases per 10,000 subjects).²¹ Interestingly, among patients with osteoporosis exposed to placebo medications, the risk for ONJ ranges from 0% to 0.02% (0-2 cases per 10,000 subjects).^{21,105} **The risk for ONJ among patients treated with either zoledronate or denosumab (0.017 – 0.04%) approximates the risk for ONJ of patients enrolled in placebo groups (0%-0.02%).**

Based on this current review of data, the risk of developing ONJ among osteoporotic patients exposed to oral, IV BPs, or denosumab is real but remains very low. The frequency of cases reported in the population (albeit very small) is likely a reflection of the massive number of patients who are exposed to these drugs.

3. Duration of medication therapy as a risk factor for MRONJ

Regardless of indications for therapy, the *duration of BP or antiresorptive therapy* continues to be a risk factor for developing ONJ. Among cancer patients exposed to zoledronate or denosumab, the incidence of developing ONJ was, respectively, 0.6 and 0.5% at 1 year, 0.9 and 1.1% at 2 years, and 1.3 and 1.1% at 3 years with the risk for ONJ among denosumab-exposed subjects plateauing between years 2 and 3.⁸⁶ In a study by Saad, et al, the

investigators combined three-blinded phase three trials and found similar results, including a plateau after 2-years for patients exposed to denosumab.¹⁰⁷ Among cancer patients exposed to zoledronate or denosumab (n=5723), the incidence of developing ONJ was, respectively, 0.5 and 0.8% at 1 year, 1.0 and 1.8% at 2 years, and 1.3 and 1.8% at 3 years.⁸⁶

For patients receiving oral bisphosphonate therapy to manage osteoporosis, the prevalence of ONJ increases over time from near 0 at baseline to 0.21% after four or more years of BP exposure (see Figure 1). The median duration of BP exposure for patients with ONJ and ONJ-like features was 4.4 years. For patients without ONJ, the median exposure to oral BPs was 3.5 years.^{101,102}

When compared to cancer patients receiving antiresorptive treatment, the risk of ONJ for patients with osteoporosis exposed to antiresorptive medications is about 100 times smaller (0.01%).

B. Local factors

1. Operative treatment

Dentoalveolar surgery is considered a major risk factor for developing MRONJ. Several studies report that among patients with MRONJ, tooth extraction is a common predisposing event ranging from 52 to 61%.^{84,107,108} In a case-control study among cancer patients exposed to zoledronate, tooth extraction was associated with a 16-fold increased risk for ONJ when compared to cancer patients without ONJ (odds ratio (OR) = 16.4; 95% confidence interval (CI), 3.4 – 79.6).¹⁰⁹ In a longitudinal cohort study in a sample of cancer patients exposed to intravenous BPs (predominately zoledronate), tooth extraction was associated with a 33-fold increased risk for ONJ.⁸⁴

The above information, while important, is not what most patients or clinicians want to know. Most clinicians and patients want to know: “Among patients exposed to antiresorptive medications, what is the risk for developing ONJ following tooth extraction (or other dentoalveolar procedures such as implant



placement or periodontal procedures)?" The best current estimate for the risk of ONJ among patients exposed to oral bisphosphonates following tooth extraction is 0.5%.¹¹⁰ The estimate was derived from a prospective evaluation of 194 patients exposed to oral BPs that underwent extraction of > 1 tooth. In this sample, one patient developed ONJ after tooth extraction.

Estimates for developing ONJ after tooth extraction among cancer patients exposed to intravenous BPs ranges from 1.6 to 14.8%. In a retrospective cohort study composed of a sample of cancer patients exposed to zoledronate (n=27), 4 (14.8%) subjects develop ONJ after tooth extraction.¹¹¹ In a prospective cohort study composed of 176 subjects with cancer who were exposed to zoledronate, 5 (2.8%) developed ONJ.¹¹² In a prospective cohort study of 63 subjects with a history of cancer and intravenous BP exposure who underwent extraction of > 1 tooth, one subject (1.6%) developed ONJ.¹¹³ Among the studies reported above, the prospective studies should be weighted more heavily due to the larger sample sizes and the prospective, not retrospective, study designs.

The risk of developing ONJ among patients who have been exposed to antiresorptive medications for other dentoalveolar operations such as dental implant placement and endodontic or periodontal procedures is unknown.

2. Anatomic factors

Limited new information regarding anatomic risk factors for MRONJ is available. MRONJ is more likely to appear in the mandible (73%) than the maxilla (22.5%) but can appear in both jaws (4.5%).¹⁰⁷ Denture use was associated with an increased risk for ONJ among cancer patients exposed to zoledronate (OR = 4.9; 95% CI = 1.2 – 20.1).¹⁰⁹ In a study by Vahtsevanos, et al, a sample of 1,621 cancer patients treated with intravenous zoledronate, ibandronate, or pamidronate, there was a 2-fold increased risk for ONJ among denture wearers.⁸⁴

3. Concomitant oral disease

Pre-existing inflammatory dental disease such as periodontal disease or periapical pathology is a well-recognized risk factor.^{111,114} Among cancer patients with MRONJ, pre-existing inflammatory dental disease was a risk factor among 50% of

the cases.^{107,111} Given that a common treatment of inflammatory dental disease is tooth extraction, it is unclear whether the pre-existing dental disease confounds the relationship between tooth extraction and risk for MRONJ noted above. It would be valuable to see an estimate of the association between tooth extraction and MRONJ adjusted for pre-existing inflammatory dental disease.

C. Demographic and systemic factors and other medication factors

Age and sex are variably reported as risk factors for MRONJ.^{84,107,109,111,114} The higher prevalence of this complication in the female population is likely a reflection of the underlying disease for which the agents are being prescribed (ie osteoporosis, breast cancer). There are very limited data describing the occurrence of MRONJ in the pediatric population. In an observational study, Brown, et al, reviewed a total of 42 pediatric patients who had received IV bisphosphonate therapy (mean duration of therapy 6.5 years) for a variety of metabolic bone diseases. No cases of ONJ were reported despite invasive dental treatment in 11 patients.¹¹⁵ The risk of developing MRONJ in the pediatric population certainly requires more complete investigation.

Corticosteroids are associated with an increased risk for MRONJ.^{107,114} Antiangiogenic agents, when given in addition to antiresorptive medications, are associated with an increased risk of ONJ.^{87,107}

Co-morbid conditions among cancer patients that are inconsistently reported to be associated with an increased risk for MRONJ include anemia (hemoglobin < 10g/dL) and diabetes.^{107,114} Cancer type is also variably reported as a risk factor.^{81,84}

Tobacco use has been inconsistently reported as a risk factor for MRONJ. In a case-control study, tobacco use approached statistical significance as a risk factor for ONJ in cancer patients (OR=3.0; 95% CI= 0.8 - 10.4).¹⁰⁹ In a more recent case-controlled study, tobacco use was not associated with ONJ in a sample of cancer patients exposed to zoledronate.¹¹⁴ Vahtsevanos did

not report an association between tobacco use and MRONJ.⁸⁴

D. Genetic factors

Since the previous position paper there have been several reports describing single nucleotide polymorphisms (SNPs) that were associated with the development MRONJ. Most of these SNPs were located within regions of the gene associated with either bone turnover, collagen formation, or certain metabolic bone diseases. Katz reported an ONJ event rate of 57% when SNPs were present in 5 candidate genes that were responsible for bone turnover.¹¹⁶ In a genome wide study, Nicoletti reported that patients with an SNP in the RBMS3 gene (associated with bone density and collagen formation) were 5.8 times more likely to develop ONJ.¹¹⁷ In a study that analyzed polymorphisms related to farnesyl diphosphate synthase activity (the enzyme specifically inhibited by bisphosphonates) a positive correlation was established with the carrier status and ONJ.¹¹⁸ Collectively, these studies suggest that a germ line sensitivity to bisphosphonates may exist.

In summary, the current literature reaffirms that the risk of MRONJ is significantly greater in cancer patients receiving antiresorptive therapy as compared to treatment regimens for osteoporosis. Moreover, the risk of MRONJ in osteoporosis patients receiving antiresorptive therapy continues to be very low regardless of drug type (bisphosphonates, denosumab) or dosing schedule. Targeted cancer therapies (VEGF and tyrosine kinase inhibitors) are also associated jaw necrosis but further studies with these medications are warranted.

Management Strategies for Patients Treated with Antiresorptives or Antiangiogenics

1. Prevention of MRONJ

The AAOMS Special Committee on MRONJ supports a multi-disciplinary approach to the treatment of patients who benefit from antiresorptive or antiangiogenic medications. This approach would include consultation with an appropriate dental professional when it is determined a patient would benefit from an antiresorptive or antiangiogenic drug. There is considerable support for early screening and initiation of appropriate dental care, which not only decreases the incidence of ONJ but would also accrue the benefits that all patients enjoy with optimum oral health.^{32,87,98,108,109,119-135}

Position Paper



The implementation of dental screening and appropriate dental measures before initiating antiresorptive therapy reduced the risk of ONJ in several prospective studies when compared in a retrospective fashion to patients who did not undergo dental preventive measures.^{53,55,107,136,137}

Dimopoulos found a statistically significant, almost threefold reduction in the incidence of osteonecrosis in patients when preventive measures were applied.⁵³ Bonacina did not report any new cases of ONJ in patients who received dental screening and necessary dental treatment before initiating IV bisphosphonate treatment.¹³⁶ Vandone found the incidence rate of developing ONJ was reduced by 50% in patients who were screened and received preventive dental care before initiating drug therapy.¹³⁷

Treatment planning for patients who may be prescribed antiresorptive or antiangiogenic therapy should include thorough examination of the oral cavity and a radiographic assessment when indicated. It is important to identify both acute infection and sites of potential infection to prevent future sequelae that could be exacerbated once drug therapies begin. Considerations during the clinical and radiographic assessment include: patient motivation, patient education regarding dental care, fluoride application, chlorhexidine rinses, tooth mobility, periodontal disease, presence of root fragments, caries, periapical pathology, edentulism, and denture fit.¹³⁸

An additional benefit of early dental consultation when the use of antiresorptive or antiangiogenic therapy is being considered is the patient being informed of the low risk associated with these drug therapies and the risk incurred by not undergoing recommended dental preventive measures before consenting to treatment.

2. Cessation of at-risk medication therapy prior to tooth extraction or other procedures, which involve osseous injury (eg dental implant placement, periodontal or apical endodontic treatment)

a. Antiresorptive Therapy for Osteoporosis/Osteopenia

The concept of a drug holiday in individuals receiving oral bisphosphonates or denosumab who



require tooth extractions has been an ongoing area of controversy with little data to support current recommendations. The *AAOMS Position Paper on Bisphosphonate-Related Osteonecrosis of the Jaw*, revised in 2009, recommended discontinuing oral bisphosphonates for 3 months prior to and 3 months following invasive dental surgery – systemic conditions permitting.¹ However there is currently no evidence that interrupting bisphosphonate therapy alters the risk of ONJ in patients following tooth extraction. In 2011 the ADA Council on Scientific Affairs revised their prior recommendation of a drug holiday and suggested that patients receiving lower cumulative doses of bisphosphonate (<2 years) or denosumab may continue antiresorptive therapy during invasive dental treatment.¹²⁵ An International ONJ Task Force recommended a drug holiday in patients at higher risk for developing ONJ, including those with greater cumulative bisphosphonate exposure (>4 years), and those with comorbid risk factors such as rheumatoid arthritis, prior or current glucocorticoid exposure, diabetes and smoking until the site has healed.¹³⁹ In a 2011 summary document on the long term safety of bisphosphonate therapy for osteoporosis, the FDA determined that there was "no substantial data available to inform decisions regarding the initiation or duration of a drug holiday."¹⁰¹

Damm and Jones proposed several alternatives to a drug holiday in BP-exposed patients who require invasive dental treatment.¹⁴⁰ While there are no studies to support these recommendations their approach is based on bone physiology and pharmacokinetics of the antiresorptive medications and merit consideration. They note that since 50% of serum BP undergoes renal excretion the major reservoir of BP is the osteoclast whose life span is 2 weeks. Thus the majority of free BP within the serum would be extremely low 2 months following the last dose of an oral bisphosphonate and a 2-month drug free period should be adequate prior to an invasive dental procedure.

This committee recognized that there is limited data to support or refute the benefits of a drug holiday for osteoporosis patients receiving antiresorptive therapy. However, a theoretical benefit may still apply for those patients with extended exposure histories (>4 yrs). Therefore the committee considers the modified drug holiday strategy as described by Damm and Jones to be a prudent approach for

those patients at risk.¹⁴⁰

b. Oncology Patients Receiving Monthly Antiresorptive Therapy

Individuals receiving monthly intravenous bisphosphonates or denosumab for treatment of oncologic disease have an increased risk of developing ONJ following tooth extraction and thus these procedures should be avoided if possible. Increased awareness, preventive dental care and early recognition of the signs and symptoms of ONJ have resulted in earlier detection. Data are scant regarding the effect of discontinuing intravenous bisphosphonates prior to invasive dental treatments should these be necessary. However, if ONJ develops the oncologist may consider discontinuing antiresorptive therapy until soft tissue closure has occurred, depending on disease status.

As a fully humanized antibody, denosumab blocks the receptor-mediated activation of osteoclasts and has no binding affinity for bone matrix. Therefore, unlike bisphosphonates, the antiresorptive effects of denosumab should be mostly dissipated within 6 months of stopping the drug. However, there are no studies to support or refute the strategy of stopping denosumab therapy in the prevention or treatment of MRONJ.

There is no data to support or refute the cessation of antiangiogenic therapy in the prevention or management of MRONJ and therefore continued research in the area is indicated.

Treatment Goals

The major goals of treatment for patients at risk of developing or who have MRONJ are:

- Prioritization and support of continued oncologic treatment in patients receiving IV antiresorptive and antiangiogenic therapy.
- o Oncology patients can benefit greatly from the therapeutic effect of antiresorptive therapy by controlling bone pain and reducing the incidence of other skeletal complications

- o The antiangiogenic class of chemotherapy agents have demonstrated efficacy in the treatment of a variety of malignancies with proven survival benefits
- Preservation of quality of life through:
 - o Patient education and reassurance
 - o Control of pain
 - o Control of secondary infection
 - o Prevention of extension of lesion and development of new areas of necrosis

Management Strategies

A. *Patients about to initiate intravenous antiresorptive or antiangiogenic treatment for cancer therapy*

The treatment objective for this group of patients is to minimize the risk of developing MRONJ. Although a small percentage of patients receiving antiresorptives develop osteonecrosis of the jaw spontaneously, the majority of affected patients experience this complication following dentoalveolar surgery.^{107,111,141-143} Therefore if systemic conditions permit, initiation of antiresorptive therapy should be delayed until dental health is optimized.^{53,55,144} This decision must be made in conjunction with the treating physician and dentist and other specialists involved in the care of the patient.

Non-restorable teeth and those with a poor prognosis should be extracted. Other necessary elective dentoalveolar surgery should also be completed at this time. Based on experience with osteoradionecrosis, it appears advisable that antiresorptive or antiangiogenic therapy should be delayed, if systemic conditions permit, until the extraction site has mucosalized (14-21 days) or until there is adequate osseous healing. Dental prophylaxis, caries control and conservative restorative dentistry are critical to maintaining functionally sound teeth. This level of care must be continued indefinitely.

Patients with full or partial dentures should be examined for areas of mucosal trauma, especially along the lingual flange region. It is critical that patients be educated as to the importance of dental hygiene and regular dental evaluations, and specifically instructed to report any pain, swelling or exposed bone.

Medical oncologists should evaluate and manage patients scheduled to receive IV antiresorptive or antiangiogenic therapy similar to those patients scheduled to initiate radiation therapy to the head and neck. The

Position Paper



osteoradionecrosis prevention protocols are guidelines that are familiar to most oncologists and general dentists.

B. *Patients about to initiate antiresorptive treatment for osteoporosis*

At the initiation of treatment, patients should be educated as to the potential risks of MRONJ as the antiresorptive therapy is likely to exceed beyond 4 years treatment. The importance of optimizing dental health throughout this treatment period and beyond should be stressed.

C. *Asymptomatic patients receiving intravenous bisphosphonates or antiangiogenic drugs for cancer*

Maintaining good oral hygiene and dental care is of paramount importance in preventing dental disease that may require dentoalveolar surgery. Procedures that involve direct osseous injury should be avoided. Non-restorable teeth may be treated by removal of the crown and endodontic treatment of the remaining roots.¹⁴⁵ Placement of dental implants should be avoided in the oncology patient receiving intravenous antiresorptive therapy or antiangiogenic medications. There is no data regarding the risk of ONJ associated with implant placement in patients receiving antiangiogenic medications.

D. *Asymptomatic patients receiving antiresorptive therapy for osteoporosis*

Sound recommendations based on strong clinical research designs are still lacking for patients taking oral bisphosphonates. The committee strategies outlined below have been updated from those in the original *Position Paper* and are based on clinical studies that demonstrate a low prevalence of disease. The risk of developing MRONJ associated with oral bisphosphonates increased when duration of therapy exceeded four years.¹⁰² Although the current level of evidence is not strong, the committee continues to consider these strategies for patients receiving oral bisphosphonates as a prudent set of guidelines that will not compromise the long-term management of their osteoporosis. As more

data become available and a better level of evidence is obtained, these strategies will be updated and modified as necessary.

Patients receiving antiresorptive therapy for osteoporosis are also at risk for developing MRONJ, but to a much lesser degree than those treated with intravenous antiresorptive therapy.^{101,102} MRONJ can develop spontaneously or after minor trauma. In general, these patients seem to have less severe manifestations of necrosis and respond more readily to stage specific treatment regimens.^{146,147} Elective dentoalveolar surgery does not appear to be contraindicated in this group. It is recommended that patients be adequately informed of the very small risk (<1%) of compromised bone healing. The risk of developing MRONJ associated with oral bisphosphonates, while exceedingly small, appears to increase when the duration of therapy exceeds 4 years.¹⁰¹ This time frame may be shortened in the presence of certain comorbidities, such as chronic corticosteroid or antiangiogenic use.^{87,107,114} If systemic conditions permit, the clinician may consider discontinuation of oral bisphosphonates for a period of two months prior to and three months following elective invasive dental surgery in order to lower the risk of MRONJ. The rationale for this approach is based on extrapolated data that demonstrate fluctuations of osteoclast function, which is related to bisphosphonate therapy, and recent outcomes studies that show improved outcome of MRONJ treatment with drug cessation.¹⁴⁰

The efficacy of utilizing a systemic marker of bone turnover to assess the risk of developing jaw necrosis in patients at risk has not been validated.^{110,148-152}

Therefore the use of systemic markers of bone turnover as a measure of MRONJ risk is not recommended although the Committee supports continued research in this area.^{53,55,144,153}

1. *For individuals who have taken an oral bisphosphonate for less than four years and have no clinical risk factors*, no alteration or delay in the planned surgery is necessary. This includes any and all procedures common to oral and maxillofacial surgeons, periodontists and other dental providers.

It is suggested that if dental implants are placed, informed consent should be provided related to possible long-term implant failure and the low risk of developing osteonecrosis of the jaws if the patient continues to take an antiresorptive

agent. These concerns are based on recent animal studies that have demonstrated impaired long-term implant healing.¹⁵⁴ Such patients should be placed on a regular recall schedule. It is also advisable to contact the provider who originally prescribed the oral bisphosphonate and suggest monitoring such patients and considering either alternate dosing of the bisphosphonate, drug holidays, or an alternative to the bisphosphonate therapy.

2. *For those patients who have taken an oral bisphosphonate for less than four years and have also taken corticosteroids or antiangiogenic medications concomitantly*, the prescribing provider should be contacted to consider discontinuation of the oral bisphosphonate (drug holiday) for at least two months prior to oral surgery, if systemic conditions permit. The antiresorptive should not be restarted until osseous healing has occurred. These strategies are based on reports that corticosteroid and antiangiogenic agents, in combination with antiresorptive therapy, may increase the risk of developing MRONJ and that a drug holiday may mitigate this risk. Long-term, prospective studies however are still required to establish the efficacy of drug holidays in reducing the risk of MRONJ for these patients.
3. *For those patients who have taken an oral bisphosphonate for more than four years with or without any concomitant medical therapy*, the prescribing provider should be contacted to consider discontinuation of the antiresorptive for two months prior to oral surgery, if systemic conditions permit. The bisphosphonate should not be restarted until osseous healing has occurred. The risk of long-term oral bisphosphonate therapy requires continued analysis and research.

E. Patients with established MRONJ

Treatment objectives for patients with an established diagnosis of MRONJ are to eliminate pain, control infection of the soft and hard tissue, and minimize the progression or occurrence of bone necrosis. Patients with established MRONJ should avoid elective den-

Position Paper





Position Paper

toalveolar surgical procedures, since these surgical sites may result in additional areas of exposed necrotic bone.

Since the publication of the 2009 guidelines there have been several reports of successful treatment outcomes for all stages of MRONJ following operative therapy (sequestrectomy, resection)^{147,155-159} and non-operative therapy.¹⁶⁰⁻¹⁶⁴ Except for the more advanced cases of Stage 3 disease or in those cases with a well-defined sequestrum, it appears that a more prudent approach would be to consider operative therapies when non-operative strategies have failed.^{160,162} Regardless of the stage of disease, areas of necrotic bone that are a constant source of soft tissue irritation and loose bony sequestra should be removed or recontoured so that soft tissue healing can be optimized.¹⁶⁵ The extraction of symptomatic teeth within exposed, necrotic bone should be considered, since it appears unlikely that the extraction will exacerbate the established necrotic process.

A randomized controlled trial of hyperbaric oxygen therapy (HBO) as an adjunct to non-surgical and surgical treatment of MRONJ demonstrated some improvement in wound healing, long-term pain scores and quality of life scores.^{166,167} However given the small sample size, there was no statistically significant difference between the control and HBO group with regard to complete gingival coverage which was a major study endpoint. Therefore the use of HBO as the sole treatment modality for MRONJ cannot be supported at this time.

Case reports with small sample sizes have documented the use of other non-surgical treatment strategies, such as platelet rich plasma,^{168,169} low-level laser irradiation,^{127,170,171} parathyroid hormone¹⁷², and bone morphogenic protein.^{168,173} The efficacy of these treatment modalities needs to be established through additional research and controlled studies.

Staging and Treatment Strategies (See Table 1)

1. Staging

Modifications in the staging system are necessary to ensure that it remains an accurate reflection of disease presentation and to assist in the appropriate stratification of patients. A Stage 0 category was added in 2009 to include patients with non-specific symptoms, or clinical and radio-

graphic abnormalities that may be due to exposure to an antiresorptive agent. At that time the risk of a patient with Stage 0 disease advancing to a higher disease stage was unknown. Since then several case studies have reported that up to 50% of patients with Stage 0 have progressed to Stage 1, 2 or 3.^{174,175} Therefore, it appears that Stage 0 may be a valid disease category that captures patients with prodromal disease (non-exposed variant). Also, the definition of exposed bone was broadened (see above) to include the presence of cutaneous or mucosal fistulae that probe to bone for Stage 1, 2 and 3 categories. Recent reports have proposed a modification of the current AAOMS staging system which is based primarily on the radiographic presentation of this disease process.^{176,177} This committee has concerns that such an approach incorporates excessively broad inclusion criteria which may overestimate disease frequency.

In order to direct rational treatment guidelines and collect data to assess the prognosis in patients who have used either IV or oral antiresorptive and antiangiogenic agents, the Committee proposes use of the following revised staging system:

Patients at risk

No apparent necrotic bone in asymptomatic patients who have been treated with IV or oral antiresorptive or antiangiogenic therapy

Stage 0 (Non-exposed bone variant)

Patients with no clinical evidence of necrotic bone, but present with non-specific symptoms or clinical and radiographic findings, such as,

Symptoms

- odontalgia not explained by an odontogenic cause
- dull, aching bone pain in the body of the mandible, which may radiate to the temporomandibular joint region
- sinus pain, which may be associated with inflammation and thickening of the maxillary sinus wall
- altered neurosensory function



Position Paper

Clinical Findings

- loosening of teeth not explained by chronic periodontal disease
- periapical/periodontal fistula that is not associated with pulpal necrosis due to caries

Radiographic Findings

- alveolar bone loss or resorption not attributable to chronic periodontal disease
- changes to trabecular pattern—dense woven bone and persistence of unremodeled bone in extraction sockets
- regions of osteosclerosis involving the alveolar bone and/or the surrounding basilar bone
- thickening/obscuring of periodontal ligament (thickening of the lamina dura and decreased size of the periodontal ligament space)¹⁵²

- oral antral/oral nasal communication
- osteolysis extending to the inferior border of the mandible or sinus floor

2. Stage-Specific Treatment Strategies

At risk – Patients who are at risk of developing MRONJ due to an exposure history with an antiresorptive or an antiangiogenic drug. They do not have exposed bone nor do they require any treatment. However, these patients should be informed of the risks of developing MRONJ, as well as the signs and symptoms of this disease process.

Stage 0 – Provide symptomatic treatment, and conservatively manage other local factors, such as caries and periodontal disease. Systemic management may include the use of medication for chronic pain and control of infection with antibiotics, when indicated. These patients will require close monitoring given the potential for progression to a higher stage of disease.

Stage 1 – These patients benefit from the use of oral antimicrobial rinses, such as chlorhexidine 0.12%. No immediate surgical treatment is required.

Stage 2 – These patients benefit from the use of oral antimicrobial rinses in combination with antibiotic therapy. Although local bone and soft tissue infection is not considered the primary etiology for this process, the colonization of the exposed bone is very common occurrence. Most of the isolated microbes have been sensitive to the penicillin group of antibiotics. Quinolones, metronidazole, clindamycin, doxycycline and erythromycin have been used with success in those patients who are allergic to penicillin. Microbial cultures should also be analyzed and the antibiotic regimen should be adjusted accordingly. Biofilm formation on the surface of the exposed bone has been described in several reports and may be responsible for the failure of systemic antibiotic therapies that are described in some refractory cases.^{66,70,178} In such cases, operative therapy directed at reducing the volume of colonized, necrotic bone may serve as a beneficial adjunct to antibiotic therapy.

Stage 3 – These patients benefit from debridement, including resection, in combination with antibiotic therapy,

These non-specific findings, which characterize this non-exposed variant of ONJ, may occur in patients with a prior history of Stage 1, 2, or 3 disease who have healed and have no clinical evidence of exposed bone.

Stage 1

Exposed and necrotic bone, or fistulae that probes to bone, in patients who are asymptomatic and have no evidence of infection. These patients may also present with radiographic findings mentioned for Stage 0 which are localized to the alveolar bone region.

Stage 2

Exposed and necrotic bone, or fistulae that probe to bone, with evidence of infection. These patients are typically symptomatic. These patients may also present with radiographic findings mentioned for Stage 0 which are localized to the alveolar bone region.

Stage 3

Exposed and necrotic bone, or fistulae that probe to bone, with evidence of infection, and one or more of the following:

- exposed necrotic bone extending beyond the region of alveolar bone, ie, inferior border and ramus in the mandible, maxillary sinus and zygoma in the maxilla
- pathologic fracture
- extra-oral fistula



which may offer long-term palliation with resolution of acute infection and pain. Symptomatic patients with stage 3 disease may require resection and immediate reconstruction with a reconstruction plate or an obturator. The potential for failure of the reconstruction plate because of the generalized effects of the bisphosphonate exposure needs to be recognized by the clinician and patient. Case reports with small sample sizes describe successful immediate reconstruction with vascularized bone.¹⁷⁹⁻¹⁸¹

Regardless of the disease stage, mobile bony sequestra should be removed to facilitate soft tissue healing. The extraction of symptomatic teeth within exposed, necrotic bone should be considered since it is unlikely that the extraction will exacerbate the established necrotic process. A thorough histologic analysis is indicated for all resected bone specimens (especially for patients with a history a malignant disease) since metastatic cancer has been reported in such specimens.¹⁸²

Table 1 Staging and Treatment Strategies

MRONJ† Staging	Treatment Strategies‡
At risk category No apparent necrotic bone in patients who have been treated with either oral or IV bisphosphonates	<ul style="list-style-type: none"> • No treatment indicated • Patient education
Stage 0 No clinical evidence of necrotic bone, but non-specific clinical findings, radiographic changes and symptoms	<ul style="list-style-type: none"> • Systemic management, including the use of pain medication and antibiotics
Stage 1 Exposed and necrotic bone, or fistulae that probes to bone, in patients who are asymptomatic and have no evidence of infection	<ul style="list-style-type: none"> • Antibacterial mouth rinse • Clinical follow-up on a quarterly basis • Patient education and review of indications for continued bisphosphonate therapy
Stage 2 Exposed and necrotic bone, or fistulae that probes to bone, associated with infection as evidenced by pain and erythema in the region of the exposed bone with or without purulent drainage	<ul style="list-style-type: none"> • Symptomatic treatment with oral antibiotics • Oral antibacterial mouth rinse • Pain control • Debridement to relieve soft tissue irritation and infection control
Stage 3 Exposed and necrotic bone or a fistula that probes to bone in patients with pain, infection, and one or more of the following: exposed and necrotic bone extending beyond the region of alveolar bone,(i.e., inferior border and ramus in the mandible, maxillary sinus and zygoma in the maxilla) resulting in pathologic fracture, extra-oral fistula, oral antral/oral nasal communication, or osteolysis extending to the inferior border of the mandible of sinus floor	<ul style="list-style-type: none"> • Antibacterial mouth rinse • Antibiotic therapy and pain control • Surgical debridement/resection for longer term palliation of infection and pain

† Exposed or probable bone in the maxillofacial region without resolution in 8-12 weeks in persons treated with a bisphosphonate who have not received radiation therapy to the jaws.

‡ Regardless of the disease stage, mobile segments of bony sequestrum should be removed without exposing uninvolved bone. The extraction of symptomatic teeth within exposed, necrotic bone should be considered since it is unlikely that the extraction will exacerbate the established necrotic process.

Future Research

The National Institutes of Health have provided funding opportunities for research on the pathophysiology of bisphosphonate-associated osteonecrosis of the jaw.¹⁸³ This has resulted in multiple research efforts focusing on several facets of this disease entity that have occurred since the last position paper. These studies are responsible for many of the new data and information that was presented in this paper. Areas of continued investigation include, but are not limited to: 1) analysis of alveolar bone hemostasis and the response to antiresorptive therapies; 2) the role of novel antiangiogenic medications and their effects on jaw bone healing; 3) pharmacogenetic research; 4) development of valid MRONJ risk assessment tools; 5) animal studies to validate existing and proposed treatment and prevention strategies.

Continued governmental and institutional support is required in order to further elucidate the underlying pathophysiological mechanisms of MRONJ at the cellular and molecular level. Moreover, improved strategies for the prevention, risk reduction, and treatment of MRONJ need to be developed further so that more accurate judgments about risk, prognosis, treatment selection, and outcome can be established for patients with MRONJ.

Position Paper



DISCLAIMER

The American Association of Oral and Maxillofacial Surgeons (AAOMS) is providing this position paper on Medication Related Osteonecrosis of the Jaw (MRONJ) to inform practitioners, patients and other interested parties. The position paper is based on a review of the existing literature and the clinical observations of a Special Committee composed of oral and maxillofacial surgeons, oral pathologists, and oncologists experienced in the diagnosis, surgical and adjunctive treatment of diseases, injuries and defects involving both the functional and esthetic aspects of the hard and soft tissues of the oral and maxillofacial regions, epidemiologists, and basic researchers.

The position paper is informational in nature and is not intended to set any standards of care. AAOMS cautions all readers that the strategies described in the position paper are NOT practice parameters or guidelines and may NOT be suitable for every, or any, purpose or application. This position paper cannot substitute for the individual judgment brought to each clinical situation by the patient's oral and maxillofacial surgeon. As with all clinical materials, the position paper reflects the science related to MRONJ at the time of the paper's development, and it should be used with the clear understanding that continued research and practice may result in new knowledge or recommendations. AAOMS makes no express or implied warranty regarding the accuracy, content, completeness, reliability, operability, or legality of information contained within the position paper, including, without limitation, the warranties of merchantability, fitness for a particular purpose, and non-infringement of proprietary rights. In no event shall the AAOMS be liable to the user of the position paper or anyone else for any decision made or action taken by him or her in reliance on such information.



Appendix I: Antiresorptive Preparations Commonly Used in the US

	Primary Indication	Nitrogen Containing	Dose	Route
Alendronate (Fosamax®)	Osteoporosis	Yes	10 mg/day 70 mg/week	Oral
Risedronate (Actonel®)	Osteoporosis	Yes	5 mg/day 35 mg/week	Oral
Ibandronate (Boniva®)	Osteoporosis	Yes	2.5 mg/day 150 mg/month	Oral
			3 mg every 3 months	IV
Pamidronate (Aredia®)	Bone Metastases	Yes	90 mg/3 weeks	IV
Zoledronate (Zometa®)	Bone Metastases	Yes	4 mg/3 weeks	IV
(Reclast®)	Osteoporosis		5 mg/year	IV
Denosumab (Xgeva®)	Bone metastases	No	120 mg/4 weeks	SQ
(Prolia®)	Osteoporosis	Humanized monoclonal antibody	60 mg/6 months	SQ

Position Paper



Appendix II: Medications Used in the Treatment of Various Cancers that are Antiangiogenic or Targets of the Vascular Endothelial Growth Factor (VEGF) Pathway that have been Associated with Jaw Necrosis*.

Drug	Mechanism of action	Primary indication
Sunitinib (Sutent®)	Tyrosine kinase inhibitor	GIST, RCC, pNET
Sorafenib (Nexavar®)	Tyrosine kinase inhibitor	HCC, RCC
Bevacizumab (Avastin®)	Humanized monoclonal antibody	mCRC, NSCLC, Glio, mRCC
Sirolimus (Rapamune®)	Mammalian target of rapamycin pathway	Organ rejection in renal transplant

Abbreviations: GIST gastrointestinal stromal tumor; RCC renal cell carcinoma; pNET pancreatic neuroendocrine tumor, HCC hepatocellular carcinoma; mCRC metastatic colorectal carcinoma; NSCLC non-squamous non-small cell lung carcinoma; Glio Glioblastoma; mRCC metastatic renal cell carcinoma

* While the FDA has issued an ONJ advisory only for bevacizumab and sunitinib (Reference), the committee remains concerned about a similar potential risk associated with several other medications within the same drug class which have a similar mechanism of action. Therefore further controlled, prospective studies will be required to more fully characterize the risk of jaw necrosis associated with these agents.



Figure 1 – Frequency of ONJ Over Time

<http://www.fda.gov/AdvisoryCommittees/CommitteesMeetingMaterials/Drugs/DrugSafetyandRiskManagementAdvisoryCommittee/ucm270957.htm> (last accessed 12/27/2013)
page 19.

Prevalence of ONJ by BP Duration

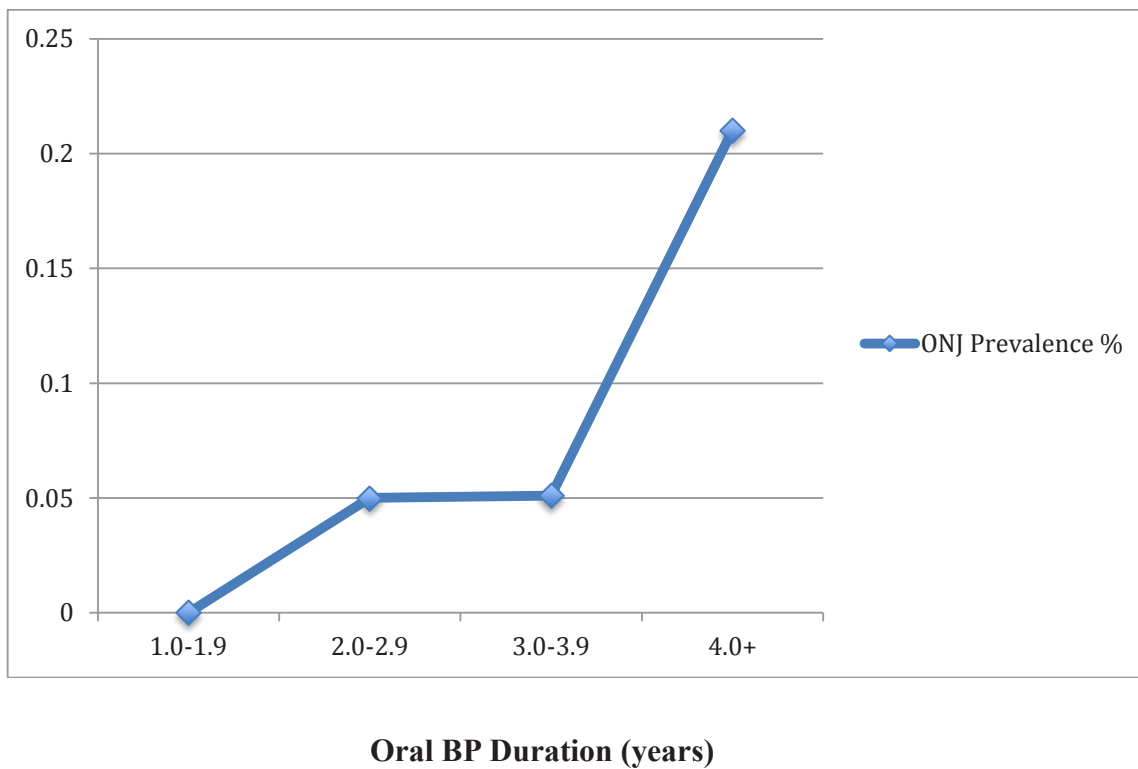




Figure 2 –

MRONJ Disease Frequency Grouped by Disease Status vs Medication Status Medications

	Placebo	Zol ²	Oral BP	Denosumab	Bevacizumab	Bevacizumab and Zolendronate	Study Design
Malignancy							
Guarneri, et al (2010)					0.2% (1076) ¹	0.9% (233)	Systemic Review
Qi, et al (2013)	0% (1450)	1.1% (2928)		1.9% (4585)			Systemic Review
Scagliotti, et al (2012)		0.8% (400)		0.7% (411)			RCT
Coleman, et al (2011)	0% (1675)	0.7% (1665)					RCT
Vahtsevanos, et al (2009)		6.7% (1163)					Prospective cohort study
Mauri, et al (2009)	0.019% (5382)	0.33% (3987)					Systemic Review
Osteoporosis							
Papapoulos, et al (2012)	0% (3383)			0.04% (4549)			RCT
Grbic, et al (2010)	0.020% (4945)	0.017% (5864)					Systemic Review
Malden, 2012			0.004% (90,000)				Prospective cohort study
Lo, 2010			0.1% ³ (8572)				Cross-sectional

¹Sample size in parentheses

²Zolendronate

³Prevalence estimate. All other frequencies reported in the figure are incidences.

1. Ruggiero SL, Dodson TB, Assael LA, et al: American Association of Oral and Maxillofacial Surgeons position paper on bisphosphonate-related osteonecrosis of the jaws--2009 update. *J Oral Maxillofac Surg* 67:2, 2009.
2. Nussbaum SR, Younger J, Vandepol CJ, et al: Single-dose intravenous therapy with pamidronate for the treatment of hypercalcemia of malignancy: comparison of 30-, 60-, and 90-mg dosages. *Am J Med* 95:297, 1993.
3. Major P, Lortholary A, Hon J, et al: Zoledronic acid is superior to pamidronate in the treatment of hypercalcemia of malignancy: a pooled analysis of two randomized, controlled clinical trials. *J Clin Oncol* 19:558, 2001.
4. Hortobagyi GN, Theriault RL, Porter L, et al: Efficacy of pamidronate in reducing skeletal complications in patients with breast cancer and lytic bone metastases. Protocol 19 Aredia Breast Cancer Study Group. *N Engl J Med* 335:1785, 1996.
5. Hortobagyi GN, Theriault RL, Lipton A, et al: Long-term prevention of skeletal complications of metastatic breast cancer with pamidronate. Protocol 19 Aredia Breast Cancer Study Group. *J Clin Oncol* 16:2038, 1998.
6. Hillner BE, Ingle JN, Chlebowski RT, et al: American Society of Clinical Oncology 2003 update on the role of bisphosphonates and bone health issues in women with breast cancer. *J Clin Oncol* 21:4042, 2003.
7. Saad F, Gleason DM, Murray R, et al: A randomized, placebo-controlled trial of zoledronic acid in patients with hormone-refractory metastatic prostate carcinoma. *J Natl Cancer Inst* 94:1458, 2002.
8. Saad F, Gleason DM, Murray R, et al: Long-term efficacy of zoledronic acid for the prevention of skeletal complications in patients with metastatic hormone-refractory prostate cancer. *J Natl Cancer Inst* 96:879, 2004.
9. Rosen LS, Gordon D, Tchekmedyan NS, et al: Long-term efficacy and safety of zoledronic acid in the treatment of skeletal metastases in patients with nonsmall cell lung carcinoma and other solid tumors: a randomized, Phase III, double-blind, placebo-controlled trial. *Cancer* 100:2613, 2004.
10. Berenson JR, Lichtenstein A, Porter L, et al: Efficacy of pamidronate in reducing skeletal events in patients with advanced multiple myeloma. Myeloma Aredia Study Group. *N Engl J Med* 334:488, 1996.
11. Berenson JR, Lichtenstein A, Porter L, et al: Long-term pamidronate treatment of advanced multiple myeloma patients reduces skeletal events. Myeloma Aredia Study Group. *J Clin Oncol* 16:593, 1998.
12. Rosen LS, Gordon D, Kaminski M, et al: Zoledronic acid versus pamidronate in the treatment of skeletal metastases in patients with breast cancer or osteolytic lesions of multiple myeloma: a phase III, double-blind, comparative trial. *Cancer J* 7:377, 2001.
13. Berenson JR, Hillner BE, Kyle RA, et al: American Society of Clinical Oncology clinical practice guidelines: the role of bisphosphonates in multiple myeloma. *J Clin Oncol* 20:3719, 2002.
14. United States. Food and Drug Administration. Center for Drug Evaluation and Research. <http://www.accessdata.fda.gov/scripts/cder/drugsatfda/index.cfm?CFID=22255647&CFTOKEN=bb-f41c75f8cb0109-1F350AA8-A3B1-DF88-62056BCE97C69DB1> Accessed February 10, 2014.
15. Physicians' Desk Reference. 57th ed. Montvale, NJ: Medical Economics; 2003.
16. Delmas PD, Meunier PJ: The management of Paget's disease of bone. *N Engl J Med* 336:558, 1997.
17. Letocha AD, Cintas HL, Troendle JF, et al: Controlled trial of pamidronate in children with types III and IV osteogenesis imperfecta confirms vertebral gains but not short-term functional improvement. *J Bone Miner Res* 20:977, 2005.
18. Watts NB: Bisphosphonate treatment of osteoporosis. *Clin Geriatr Med* 19:395, 2003.
19. Delmas PD: The use of bisphosphonates in the treatment of osteoporosis. *Curr Opin Rheumatol* 17:462, 2005.
20. Cummings SR, San Martin J, McClung MR, et al: Denosumab for prevention of fractures in postmenopausal women with osteoporosis. *N Engl J Med* 361:756, 2009.
21. Papapoulos S, Chapurlat R, Libanati C, et al: Five years of denosumab exposure in women with postmenopausal osteoporosis: results from the first two years of the FREEDOM extension. *J Bone Miner Res* 27:694, 2012.
22. Fizazi K, Carducci M, Smith M, et al: Denosumab versus zoledronic acid for treatment of bone metastases in men with castration-resistant prostate cancer: a randomised, double-blind study. *Lancet* 377:813, 2011.
23. Stopeck A, Body JJ, Fujiwara Y, et al: Denosumab versus zoledronic acid for the treatment of breast cancer patients with bone metastases: results of a randomized phase 3 study. *Eur J Cancer Supplements [EJC supplements]* 7:2, 2009.
24. Marx RE: Pamidronate (Aredia) and zoledronate (Zometa) induced avascular necrosis of the jaws: a growing epidemic. *J Oral Maxillofac Surg* 61:1115, 2003.
25. Ruggiero SL, Mehrotra B, Rosenberg TJ, et al: Osteonecrosis of the jaws associated with the use of bisphosphonates: a review of 63 cases. *J Oral Maxillofac Surg* 62:527, 2004.

Position Paper

26. Hohnacker JA: *Dear Doctor. Precautions added to the label of Aredia and Zometa ed. East Hanover, NJ: Novartis Oncology; September 24, 2004:2.*
27. United States. Food and Drug Administration. *Oncologic Drugs Advisory Committee. Combidex briefing information.* http://www.fda.gov/ohrms/dockets/ac/05/briefing/2005-4095B1_01_01-AdvancedMag-Combidex.pdf Accessed February 10, 2014.
28. United States. Food and Drug Administration. Office of Drug Safety. *Postmarketing Safety Review. Bisphosphonates.* http://www.fda.gov/ohrms/dockets/ac/05/briefing/2005-4095B2_03_04-FDA-Tab3.pdf Accessed February 10, 2014.
29. Reid IR, Bolland MJ, Grey AB: *Is bisphosphonate-associated osteonecrosis of the jaw caused by soft tissue toxicity? Bone 41:318, 2007.*
30. Allen MR, Burr DB: *The pathogenesis of bisphosphonate-related osteonecrosis of the jaw: so many hypotheses, so few data. J Oral Maxillofac Surg 67:61, 2009.*
31. Landesberg R, Woo V, Cremers S, et al: *Potential pathophysiological mechanisms in osteonecrosis of the jaw. Ann N Y Acad Sci 1218:62, 2011.*
32. Yamashita J, McCauley LK: *Antiresorptives and osteonecrosis of the jaw. J Evid Based Dent Pract 12:233, 2012.*
33. Bamias A, Kastritis E, Bamia C, et al: *Osteonecrosis of the jaw in cancer after treatment with bisphosphonates: incidence and risk factors. J Clin Oncol 23:8580, 2005.*
34. Bi Y, Gao Y, Ehrichou D, et al: *Bisphosphonates cause osteonecrosis of the jaw-like disease in mice. Am J Pathol 177:280, 2010.*
35. Hokugo A, Christensen R, Chung EM, et al: *Increased prevalence of bisphosphonate-related osteonecrosis of the jaw with vitamin D deficiency in rats. J Bone Miner Res 25:1337, 2010.*
36. Mortensen M, Lawson W, Montazem A: *Osteonecrosis of the jaw associated with bisphosphonate use: Presentation of seven cases and literature review. Laryngoscope 117:30, 2007.*
37. Sonis ST, Watkins BA, Lyng GD, et al: *Bony changes in the jaws of rats treated with zoledronic acid and dexamethasone before dental extractions mimic bisphosphonate-related osteonecrosis in cancer patients. Oral Oncol 45:164, 2009.*
38. Mehrotra B, Ruggiero S: *Bisphosphonate complications including osteonecrosis of the jaw. Hematology Am Soc Hematol Educ Program:356, 2006.*
39. Ruggiero SL, Fantasia J, Carlson E: *Bisphosphonate-related osteonecrosis of the jaw: background and guidelines for diagnosis, staging and management. Oral Surg Oral Med Oral Pathol Oral Radiol Endod 102:433, 2006.*
40. Wood J, Bonjean K, Ruetz S, et al: *Novel antiangiogenic effects of the bisphosphonate compound zoledronic acid. J Pharmacol Exp Ther 302:1055, 2002.*
41. Baron R, Ferrari S, Russell RG: *Denosumab and bisphosphonates: different mechanisms of action and effects. Bone 48:677, 2011.*
42. Lacey DL, Boyle WJ, Simonet WS, et al: *Bench to bedside: elucidation of the OPG-RANK-RANKL pathway and the development of denosumab. Nat Rev Drug Discov 11:401, 2012.*
43. Russell RG, Watts NB, Ebetino FH, et al: *Mechanisms of action of bisphosphonates: similarities and differences and their potential influence on clinical efficacy. Osteoporos Int 19:733, 2008.*
44. Roelofs AJ, Thompson K, Gordon S, et al: *Molecular mechanisms of action of bisphosphonates: current status. Clin Cancer Res 12:6222s, 2006.*
45. Russell RG, Rogers MJ: *Bisphosphonates: from the laboratory to the clinic and back again. Bone 25:97, 1999.*
46. Aghaloo TL, Kang B, Sung EC, et al: *Periodontal disease and bisphosphonates induce osteonecrosis of the jaws in the rat. J Bone Miner Res 26:1871, 2011.*
47. Allen MR, Burr DB: *Mandible matrix necrosis in beagle dogs after 3 years of daily oral bisphosphonate treatment. J Oral Maxillofac Surg 66:987, 2008.*
48. Lipton A, Fizazi K, Stopeck AT, et al: *Superiority of denosumab to zoledronic acid for prevention of skeletal-related events: a combined analysis of 3 pivotal, randomised, phase 3 trials. Eur J Cancer 48:3082, 2012.*
49. Sinnigen K, Tsourdi E, Rauner M, et al: *Skeletal and extraskelatal actions of denosumab. Endocrine 42:52, 2012.*
50. Aghaloo TL, Felsenfeld AL, Tetradis S: *Osteonecrosis of the jaw in a patient on Denosumab. J Oral Maxillofac Surg 68:959, 2010.*
51. Kuroshima S, Kovacic BL, Kozloff KM, et al: *Intra-oral PTH administration promotes tooth extraction socket healing. J Dent Res 92:553, 2013.*
52. Dayisoğlu EH, Senel FC, Ungor C, et al: *The effects of adjunctive parathyroid hormone injection on bisphosphonate-related osteonecrosis of the jaws: an animal study. Int J Oral Maxillofac Surg 42:1475, 2013.*
53. Dimopoulos MA, Kastritis E, Bamia C, et al: *Reduction of osteonecrosis of the jaw (ONJ) after implementation of preventive measures in patients with multiple myeloma treated with zoledronic acid. Ann Oncol 20:117, 2009.*
54. Hoff AO, Toth BB, Altundag K, et al: *Frequency and risk factors associated with osteonecrosis of the jaw in cancer patients treated with intravenous bisphosphonates. J Bone Miner Res 23:826, 2008.*

55. Ripamonti CI, Maniezzo M, Campa T, et al: Decreased occurrence of osteonecrosis of the jaw after implementation of dental preventive measures in solid tumour patients with bone metastases treated with bisphosphonates. The experience of the National Cancer Institute of Milan. *Ann Oncol* 20:137, 2009.
56. Boonyapakorn T, Schirmer I, Reichart PA, et al: Bisphosphonate-induced osteonecrosis of the jaws: prospective study of 80 patients with multiple myeloma and other malignancies. *Oral Oncol* 44:857, 2008.
57. Marx R: *Oral and Intravenous Bisphosphonate Induced Osteonecrosis of the Jaws: History, etiology, prevention, and treatment.* 2nd ed. Hanover Park, IL: Quintessence Publishing Co; 2011.
58. Marx RE, Sawatari Y, Fortin M, et al: Bisphosphonate-induced exposed bone (osteonecrosis/osteopetrosis) of the jaws: risk factors, recognition, prevention, and treatment. *J Oral Maxillofac Surg* 63:1567, 2005.
59. Ficarra G, Beninati F, Rubino I, et al: Osteonecrosis of the jaws in periodontal patients with a history of bisphosphonates treatment. *J Clin Periodontol* 32:1123, 2005.
60. Aguirre JJ, Akhter MP, Kimmel DB, et al: Oncologic doses of zoledronic acid induce osteonecrosis of the jaw-like lesions in rice rats (*Oryzomys palustris*) with periodontitis. *J Bone Miner Res* 27:2130, 2012.
61. Kang B, Cheong S, Chaichanasakul T, et al: Periapical disease and bisphosphonates induce osteonecrosis of the jaws in mice. *J Bone Miner Res* 28:1631, 2013.
62. Mawardi H, Treister N, Richardson P, et al: Sinus tracts--an early sign of bisphosphonate-associated osteonecrosis of the jaws? *J Oral Maxillofac Surg* 67:593, 2009.
63. Lopez-Jornet P, Camacho-Alonso F, Martinez-Canovas A, et al: Perioperative antibiotic regimen in rats treated with pamidronate plus dexamethasone and subjected to dental extraction: a study of the changes in the jaws. *J Oral Maxillofac Surg* 69:2488, 2011.
64. Gotcher JE, Jee WS: The progress of the periodontal syndrome in the rice rat. I. Morphometric and autoradiographic studies. *J Periodontol Res* 16:275, 1981.
65. Hansen T, Kunkel M, Weber A, et al: Osteonecrosis of the jaws in patients treated with bisphosphonates - histomorphologic analysis in comparison with infected osteoradionecrosis. *J Oral Pathol Med* 35:155, 2006.
66. Sedghizadeh PP, Kumar SK, Gorur A, et al: Identification of microbial biofilms in osteonecrosis of the jaws secondary to bisphosphonate therapy. *J Oral Maxillofac Surg* 66:767, 2008.
67. Kos M, Junka A, Smutnicka D, et al: Pamidronate enhances bacterial adhesion to bone hydroxyapatite. Another puzzle in the pathology of bisphosphonate-related osteonecrosis of the jaw? *J Oral Maxillofac Surg* 71:1010, 2013.
68. Sedghizadeh PP, Kumar SK, Gorur A, et al: Microbial biofilms in osteomyelitis of the jaw and osteonecrosis of the jaw secondary to bisphosphonate therapy. *J Am Dent Assoc* 140:1259, 2009.
69. Sedghizadeh PP, Yooseph S, Fadrosh DW, et al: Metagenomic investigation of microbes and viruses in patients with jaw osteonecrosis associated with bisphosphonate therapy. *Oral Surg Oral Med Oral Pathol Oral Radiol* 114:764, 2012.
70. Wanger G, Gorby Y, El-Naggar MY, et al: Electrically conductive bacterial nanowires in bisphosphonate-related osteonecrosis of the jaw biofilms. *Oral Surg Oral Med Oral Pathol Oral Radiol* 115:71, 2013.
71. Kim HK: Introduction to osteonecrosis of the femoral head (OFH) and osteonecrosis of the jaw (ONJ). *J Musculoskelet Neuronal Interact* 7:350, 2007.
72. Bezzi M, Hasmim M, Bieler G, et al: Zoledronate sensitizes endothelial cells to tumor necrosis factor-induced programmed cell death: evidence for the suppression of sustained activation of focal adhesion kinase and protein kinase B/Akt. *J Biol Chem* 278:43603, 2003.
73. Santini D, Vincenzi B, Dicuonzo G, et al: Zoledronic acid induces significant and long-lasting modifications of circulating angiogenic factors in cancer patients. *Clin Cancer Res* 9:2893, 2003.
74. Lin JH: Bisphosphonates: a review of their pharmacokinetic properties. *Bone* 18:75, 1996.
75. Giraudo E, Inoue M, Hanahan D: An amino-bisphosphonate targets MMP-9-expressing macrophages and angiogenesis to impair cervical carcinogenesis. *J Clin Invest* 114:623, 2004.
76. Montague R, Hart CA, George NJ, et al: Differential inhibition of invasion and proliferation by bisphosphonates: anti-metastatic potential of Zoledronic acid in prostate cancer. *Eur Urol* 46:389, 2004.
77. Landesberg R, Cozin M, Cremers S, et al: Inhibition of oral mucosal cell wound healing by bisphosphonates. *J Oral Maxillofac Surg* 66:839, 2008.
78. Reid IR, Cornish J: Epidemiology and pathogenesis of osteonecrosis of the jaw. *Nat Rev Rheumatol* 8:90, 2012.
79. Ali-Erdem M, Burak-Cankaya A, Cemil-Isler S, et al: Extraction socket healing in rats treated with bisphosphonate: animal model for bisphosphonate related osteonecrosis of jaws in multiple myeloma patients. *Med Oral Patol Oral Cir Bucal* 16:e879, 2011.
80. Kikuri T, Kim I, Yamaza T, et al: Cell-based immunotherapy with mesenchymal stem cells cures bisphosphonate-related osteonecrosis of the jaw-like disease in mice. *J Bone Miner Res* 25:1668, 2010.

Position Paper

81. Qi WX, Tang LN, He AN, et al: Risk of osteonecrosis of the jaw in cancer patients receiving denosumab: a meta-analysis of seven randomized controlled trials. *Int J Clin Oncol* 2013.
82. Coleman R, Woodward E, Brown J, et al: Safety of zoledronic acid and incidence of osteonecrosis of the jaw (ONJ) during adjuvant therapy in a randomised phase III trial (AZURE: BIG 01-04) for women with stage II/III breast cancer. *Breast Cancer Res Treat* 127:429, 2011.
83. Mauri D, Valachis A, Polyzos IP, et al: Osteonecrosis of the jaw and use of bisphosphonates in adjuvant breast cancer treatment: a meta-analysis. *Breast Cancer Res Treat* 116:433, 2009.
84. Vahtsevanos K, Kyrgidis A, Verrou E, et al: Longitudinal cohort study of risk factors in cancer patients of bisphosphonate-related osteonecrosis of the jaw. *J Clin Oncol* 27:5356, 2009.
85. Scagliotti GV, Hirsh V, Siena S, et al: Overall survival improvement in patients with lung cancer and bone metastases treated with denosumab versus zoledronic acid: subgroup analysis from a randomized phase 3 study. *J Thorac Oncol* 7:1823, 2012.
86. Henry DH, Costa L, Goldwasser F, et al: Randomized, double-blind study of denosumab versus zoledronic acid in the treatment of bone metastases in patients with advanced cancer (excluding breast and prostate cancer) or multiple myeloma. *J Clin Oncol* 29:1125, 2011.
87. Guarneri V, Miles D, Robert N, et al: Bevacizumab and osteonecrosis of the jaw: incidence and association with bisphosphonate therapy in three large prospective trials in advanced breast cancer. *Breast Cancer Res Treat* 122:181, 2010.
88. Koch FP, Walter C, Hansen T, et al: Osteonecrosis of the jaw related to sunitinib. *Oral Maxillofac Surg* 15:63, 2011.
89. Nicolatou-Galitis O, Migkou M, Psyrris A, et al: Gingival bleeding and jaw bone necrosis in patients with metastatic renal cell carcinoma receiving sunitinib: report of 2 cases with clinical implications. *Oral Surg Oral Med Oral Pathol Oral Radiol* 113:234, 2012.
90. Fleissig Y, Regev E, Lehman H: Sunitinib related osteonecrosis of jaw: a case report. *Oral Surg Oral Med Oral Pathol Oral Radiol* 113:e1, 2012.
91. Brunello A, Saia G, Bedogni A, et al: Worsening of osteonecrosis of the jaw during treatment with sunitinib in a patient with metastatic renal cell carcinoma. *Bone* 44:173, 2009.
92. Ayllon J, Launay-Vacher V, Medioni J, et al: Osteonecrosis of the jaw under bisphosphonate and antiangiogenic therapies: cumulative toxicity profile? *Ann Oncol* 20:600, 2009.
93. Christodoulou C, Pervena A, Klouvas G, et al: Combination of bisphosphonates and antiangiogenic factors induces osteonecrosis of the jaw more frequently than bisphosphonates alone. *Oncology* 76:209, 2009.
94. Balmor GR, Yarom N, Weitzen R: Drug-induced palate osteonecrosis following nasal surgery. *Isr Med Assoc J* 14:193, 2012.
95. Hoefert S, Eufinger H: Sunitinib may raise the risk of bisphosphonate-related osteonecrosis of the jaw: presentation of three cases. *Oral Surg Oral Med Oral Pathol Oral Radiol Endod* 110:463, 2010.
96. Bozas G, Roy A, Ramasamy V, et al: Osteonecrosis of the jaw after a single bisphosphonate infusion in a patient with metastatic renal cancer treated with sunitinib. *Onkologie* 33:321, 2010.
97. Beuselink B, Wolter P, Karadimou A, et al: Concomitant oral tyrosine kinase inhibitors and bisphosphonates in advanced renal cell carcinoma with bone metastases. *Br J Cancer* 107:1665, 2012.
98. Smidt-Hansen T, Folkmar TB, Fode K, et al: Combination of zoledronic Acid and targeted therapy is active but may induce osteonecrosis of the jaw in patients with metastatic renal cell carcinoma. *J Oral Maxillofac Surg* 71:1532, 2013.
99. United States. Food and Drug Administration. Avastin (bevacizumab) Safety Information. <http://www.fda.gov/Safety/MedWatch/SafetyInformation/ucm275758.htm> Accessed March 13, 2014.
100. United States. Food and Drug Administration. Sutent (sunitinib malate) capsules Safety Information. <http://www.fda.gov/safety/medwatch/safetyinformation/ucm224050.htm>. Accessed March 13, 2014.
101. Background Document for Meeting of Advisory Committee for Reproductive Health Drugs and Drug Safety and Risk Management Advisory Committee. United States. Food and Drug Administration. September 9, 2011; <http://www.fda.gov/downloads/Advisory-Committees/CommitteesMeetingMaterials/drugs/DrugSafetyandRiskManagementAdvisoryCommittee/ucm270958.pdf> Accessed February 10, 2014.
102. Lo JC, O'Ryan FS, Gordon NP, et al: Prevalence of osteonecrosis of the jaw in patients with oral bisphosphonate exposure. *J Oral Maxillofac Surg* 68:243, 2010.
103. Felsenberg D, Hoffmeister B: [Necrosis of the jaw after high-dose bisphosphonate therapy.] *Kiefernekrosen nach hoch dosierter Bisphosphonattherapie. Dtsch Arztebl* 103:3078, 2006.
104. Malden N, Lopes V: An epidemiological study of alendronate-related osteonecrosis of the jaws. A case series from the south-east of Scotland with attention given to case definition and prevalence. *J Bone Miner Metab* 30:171, 2012.
105. Grbic JT, Black DM, Lyles KW, et al: The incidence of osteonecrosis of the jaw in patients receiving 5 milligrams of zoledronic acid: data from the health outcomes and reduced incidence with zoledronic acid once yearly clinical trials program. *J Am Dent Assoc* 141:1365, 2010.

106. Black DM, Reid IR, Boonen S, et al: The effect of 3 versus 6 years of zoledronic acid treatment of osteoporosis: a randomized extension to the HORIZON-Pivotal Fracture Trial (PFT). *J Bone Miner Res* 27:243, 2012.
107. Saad F, Brown JE, Van Poznak C, et al: Incidence, risk factors, and outcomes of osteonecrosis of the jaw: integrated analysis from three blinded active-controlled phase III trials in cancer patients with bone metastases. *Ann Oncol* 23:1341, 2012.
108. Fehm T, Beck V, Banys M, et al: Bisphosphonate-induced osteonecrosis of the jaw (ONJ): Incidence and risk factors in patients with breast cancer and gynecological malignancies. *Gynecol Oncol* 112:605, 2009.
109. Kyrgidis A, Vahtsevanos K, Koloutsos G, et al: Bisphosphonate-related osteonecrosis of the jaws: a case-control study of risk factors in breast cancer patients. *J Clin Oncol* 26:4634, 2008.
110. Kunchur R, Need A, Hughes T, et al: Clinical investigation of C-terminal cross-linking telopeptide test in prevention and management of bisphosphonate-associated osteonecrosis of the jaws. *J Oral Maxillofac Surg* 67:1167, 2009.
111. Yamazaki T, Yamori M, Ishizaki T, et al: Increased incidence of osteonecrosis of the jaw after tooth extraction in patients treated with bisphosphonates: a cohort study. *Int J Oral Maxillofac Surg* 41:1397, 2012.
112. Mozzati M, Arata V, Gallesio G: Tooth extraction in patients on zoledronic acid therapy. *Oral Oncol* 48:817, 2012.
113. Scoletta M, Arata V, Arduino PG, et al: Tooth extractions in intravenous bisphosphonate-treated patients: a refined protocol. *J Oral Maxillofac Surg* 71:994, 2013.
114. Tsao C, Darby I, Ebeling PR, et al: Oral health risk factors for bisphosphonate-associated jaw osteonecrosis. *J Oral Maxillofac Surg* 71:1360, 2013.
115. Brown JJ, Ramalingam L, Zacharin MR: Bisphosphonate-associated osteonecrosis of the jaw: does it occur in children? *Clin Endocrinol (Oxf)* 68:863, 2008.
116. Katz J, Gong Y, Salmasinia D, et al: Genetic polymorphisms and other risk factors associated with bisphosphonate induced osteonecrosis of the jaw. *Int J Oral Maxillofac Surg* 40:605, 2011.
117. Nicoletti P, Cartsos VM, Palaska PK, et al: Genomewide pharmacogenetics of bisphosphonate-induced osteonecrosis of the jaw: the role of RBMS3. *Oncologist* 17:279, 2012.
118. Marini F, Tonelli P, Cavalli L, et al: Pharmacogenetics of bisphosphonate-associated osteonecrosis of the jaw. *Front Biosci (Elite Ed)* 3:364, 2011.
119. Sivoilella S, Lumachi F, Stellini E, et al: Denosumab and anti-angiogenic drug-related osteonecrosis of the jaw: an uncommon but potentially severe disease. *Anticancer Res* 33:1793, 2013.
120. Epstein MS, Epstein JB, Ephros HD: The effects of osteoclast modifiers on the oral cavity: a review for prescribers. *Curr Opin Support Palliat Care* 6:337, 2012.
121. Vescovi P, Merigo E, Meleti M, et al: Bisphosphonates-related osteonecrosis of the jaws: a concise review of the literature and a report of a single-centre experience with 151 patients. *J Oral Pathol Med* 41:214, 2012.
122. Schubert M, Klatter I, Linek W, et al: The Saxon bisphosphonate register - therapy and prevention of bisphosphonate-related osteonecrosis of the jaws. *Oral Oncol* 48:349, 2012.
123. Shannon J, Shannon J, Modelevsky S, et al: Bisphosphonates and osteonecrosis of the jaw. *J Am Geriatr Soc* 59:2350, 2011.
124. Lo JC, O'Ryan F, Yang J, et al: Oral health considerations in older women receiving oral bisphosphonate therapy. *J Am Geriatr Soc* 59:916, 2011.
125. Hellstein JW, Adler RA, Edwards B, et al: Managing the care of patients receiving antiresorptive therapy for prevention and treatment of osteoporosis: executive summary of recommendations from the American Dental Association Council on Scientific Affairs. *J Am Dent Assoc* 142:1243, 2011.
126. Patel V, McLeod NM, Rogers SN, et al: Bisphosphonate osteonecrosis of the jaw--a literature review of UK policies versus international policies on bisphosphonates, risk factors and prevention. *Br J Oral Maxillofac Surg* 49:251, 2011.
127. Atalay B, Yalcin S, Emes Y, et al: Bisphosphonate-related osteonecrosis: laser-assisted surgical treatment or conventional surgery? *Lasers Med Sci* 26:815, 2011.
128. Aapro M, Saad F, Costa L: Optimizing clinical benefits of bisphosphonates in cancer patients with bone metastases. *Oncologist* 15:1147, 2010.
129. Fehm T, Felsenberg D, Krimmel M, et al: Bisphosphonate-associated osteonecrosis of the jaw in breast cancer patients: recommendations for prevention and treatment. *Breast* 18:213, 2009.
130. Walter C, Al-Nawas B, du Bois A, et al: Incidence of bisphosphonate-associated osteonecrosis of the jaws in breast cancer patients. *Cancer* 115:1631, 2009.
131. Khan AA, Sandor GK, Dore E, et al: Bisphosphonate associated osteonecrosis of the jaw. *J Rheumatol* 36:478, 2009.
132. Dickinson M, Prince HM, Kirsas S, et al: Osteonecrosis of the jaw complicating bisphosphonate treatment for bone disease in multiple myeloma: an overview with recommendations for prevention and treatment. *Intern Med J* 39:304, 2009.

Position Paper

133. Edwards BJ, Hellstein JW, Jacobsen PL, et al: Updated recommendations for managing the care of patients receiving oral bisphosphonate therapy: an advisory statement from the American Dental Association Council on Scientific Affairs. *J Am Dent Assoc* 139:1674, 2008.
134. Abu-Id MH, Warnke PH, Gottschalk J, et al: "Bis-phossy jaws" - high and low risk factors for bisphosphonate-induced osteonecrosis of the jaw. *J Craniomaxillofac Surg* 36:95, 2008.
135. Kyle RA, Yee GC, Somerfield MR, et al: American Society of Clinical Oncology 2007 clinical practice guideline update on the role of bisphosphonates in multiple myeloma. *J Clin Oncol* 25:2464, 2007.
136. Bonacina R, Mariani U, Villa F, et al: Preventive strategies and clinical implications for bisphosphonate-related osteonecrosis of the jaw: a review of 282 patients. *J Can Dent Assoc* 77:b147, 2011.
137. Vandone AM, Donadio M, Mozzati M, et al: Impact of dental care in the prevention of bisphosphonate-associated osteonecrosis of the jaw: a single-center clinical experience. *Ann Oncol* 23:193, 2012.
138. Hinchy NV, Jayaprakash V, Rossitto RA, et al: Osteonecrosis of the jaw - prevention and treatment strategies for oral health professionals. *Oral Oncol* 49:878, 2013.
139. Khan AA, Morrison A, Hanley DA, et al: International Consensus on Diagnosis and Management of Osteonecrosis of the Jaw. 2013:22.
140. Damm DD, Jones DM: Bisphosphonate-related osteonecrosis of the jaws: a potential alternative to drug holidays. *Gen Dent* 61:33, 2013.
141. Durie BG, Katz M, Crowley J: Osteonecrosis of the jaw and bisphosphonates. *N Engl J Med* 353:99, 2005.
142. Hoff AO, Toth BB, Altundag K, et al: Osteonecrosis of the jaw in patients receiving intravenous bisphosphonate therapy. *J Clin Oncol* 24:8528, 2006.
143. Badros A, Weikel D, Salama A, et al: Osteonecrosis of the jaw in multiple myeloma patients: clinical features and risk factors. *J Clin Oncol* 24:945, 2006.
144. Mehrotra B, Fantasia J, Ruggiero SL: Outcomes of bisphosphonate related osteonecrosis of the jaw. Importance of staging and management. A large single institution update. *J Clin Oncol* 26:20526, 2008.
145. Endodontic Implications of Bisphosphonate-Associated Osteonecrosis of the Jaws. Chicago, IL: American Association of Endodontists; 2010:4.
146. Marx RE, Cillo JE, Jr., Ulloa JJ: Oral bisphosphonate-induced osteonecrosis: risk factors, prediction of risk using serum CTX testing, prevention, and treatment. *J Oral Maxillofac Surg* 65:2397, 2007.
147. Carlson ER, Basile JD: The role of surgical resection in the management of bisphosphonate-related osteonecrosis of the jaws. *J Oral Maxillofac Surg* 67:85, 2009.
148. Bagan JV, Jimenez Y, Gomez D, et al: Collagen telopeptide (serum CTX) and its relationship with the size and number of lesions in osteonecrosis of the jaws in cancer patients on intravenous bisphosphonates. *Oral Oncol* 44:1088, 2008.
149. Kwon YD, Kim DY, Ohe JY, et al: Correlation between serum C-terminal cross-linking telopeptide of type I collagen and staging of oral bisphosphonate-related osteonecrosis of the jaws. *J Oral Maxillofac Surg* 67:2644, 2009.
150. Lehrer S, Montazem A, Ramanathan L, et al: Normal serum bone markers in bisphosphonate-induced osteonecrosis of the jaws. *Oral Surg Oral Med Oral Pathol Oral Radiol Endod* 106:389, 2008.
151. Migliorati CA, Saunders D, Conlon MS, et al: Assessing the association between bisphosphonate exposure and delayed mucosal healing after tooth extraction. *J Am Dent Assoc* 144:406, 2013.
152. Fleisher KE, Welch G, Kottal S, et al: Predicting risk for bisphosphonate-related osteonecrosis of the jaws: CTX versus radiographic markers. *Oral Surg Oral Med Oral Pathol Oral Radiol Endod* 110:509, 2010.
153. Rosen HN, Moses AC, Garber J, et al: Serum CTX: a new marker of bone resorption that shows treatment effect more often than other markers because of low coefficient of variability and large changes with bisphosphonate therapy. *Calcif Tissue Int* 66:100, 2000.
154. Kim I, Ki H, Lee W, et al: The effect of systemically administered bisphosphonates on bony healing after tooth extraction and osseointegration of dental implants in the rabbit maxilla. *Int J Oral Maxillofac Implants* 28:1194, 2013.
155. Graziani F, Vescovi P, Campisi G, et al: Resective surgical approach shows a high performance in the management of advanced cases of bisphosphonate-related osteonecrosis of the jaws: a retrospective survey of 347 cases. *J Oral Maxillofac Surg* 70:2501, 2012.
156. Stanton DC, Balasanian E: Outcome of surgical management of bisphosphonate-related osteonecrosis of the jaws: review of 33 surgical cases. *J Oral Maxillofac Surg* 67:943, 2009.
157. Stockmann P, Vairaktaris E, Wehrhan F, et al: Osteotomy and primary wound closure in bisphosphonate-associated osteonecrosis of the jaw: a prospective clinical study with 12 months follow-up. *Support Care Cancer* 18:449, 2010.
158. Mucke T, Koschinski J, Deppe H, et al: Outcome of treatment and parameters influencing recurrence in patients with bisphosphonate-related osteonecrosis of the jaws. *J Cancer Res Clin Oncol* 137:907, 2011.

Position Paper

159. Eckardt AM, Lemound J, Lindhorst D, et al: Surgical management of bisphosphonate-related osteonecrosis of the jaw in oncologic patients: a challenging problem. *Anticancer Res* 31:2313, 2011.
160. Ferlito S, Puzzo S, Palermo F, et al: Treatment of bisphosphonate-related osteonecrosis of the jaws: presentation of a protocol and an observational longitudinal study of an Italian series of cases. *Br J Oral Maxillofac Surg* 50:425, 2012.
161. Saussez S, Javadian R, Hupin C, et al: Bisphosphonate-related osteonecrosis of the jaw and its associated risk factors: a Belgian case series. *Laryngoscope* 119:323, 2009.
162. Scoletta M, Arduino PG, Dalmaso P, et al: Treatment outcomes in patients with bisphosphonate-related osteonecrosis of the jaws: a prospective study. *Oral Surg Oral Med Oral Pathol Oral Radiol Endod* 110:46, 2010.
163. Van den Wyngaert T, Claeyts T, Huizing MT, et al: Initial experience with conservative treatment in cancer patients with osteonecrosis of the jaw (ONJ) and predictors of outcome. *Ann Oncol* 20:331, 2009.
164. Wutzl A, Biedermann E, Wanschitz F, et al: Treatment results of bisphosphonate-related osteonecrosis of the jaws. *Head Neck* 30:1224, 2008.
165. Kademani D, Koka S, Lacy MQ, et al: Primary surgical therapy for osteonecrosis of the jaw secondary to bisphosphonate therapy. *Mayo Clin Proc* 81:1100, 2006.
166. Freiburger JJ, Padilla-Burgos R, McGraw T, et al: What is the role of hyperbaric oxygen in the management of bisphosphonate-related osteonecrosis of the jaw: a randomized controlled trial of hyperbaric oxygen as an adjunct to surgery and antibiotics. *J Oral Maxillofac Surg* 70:1573, 2012.
167. Freiburger JJ: Utility of hyperbaric oxygen in treatment of bisphosphonate-related osteonecrosis of the jaws. *J Oral Maxillofac Surg* 67:96, 2009.
168. Lee CY, David T, Nishime M: Use of platelet-rich plasma in the management of oral bisphosphonate-associated osteonecrosis of the jaw: a report of 2 cases. *J Oral Implantol* 33:371, 2007.
169. Soydan SS, Uckan S: Management of bisphosphonate-related osteonecrosis of the jaw with a platelet-rich fibrin membrane: technical report. *J Oral Maxillofac Surg* 72:322, 2014.
170. Scoletta M, Arduino PG, Reggio L, et al: Effect of low-level laser irradiation on bisphosphonate-induced osteonecrosis of the jaws: preliminary results of a prospective study. *Photomed Laser Surg* 28:179, 2010.
171. Vescovi P, Merigo E, Manfredi M, et al: Nd:YAG laser biostimulation in the treatment of bisphosphonate-associated osteonecrosis of the jaw: clinical experience in 28 cases. *Photomed Laser Surg* 26:37, 2008.
172. Bashutski JD, Eber RM, Kinney JS, et al: Teriparatide and osseous regeneration in the oral cavity. *N Engl J Med* 363:2396, 2010.
173. Gerard DA, Carlson ER, Gotcher JE, et al: Early inhibitory effects of zoledronic acid in tooth extraction sockets in dogs are negated by recombinant human bone morphogenetic protein. *J Oral Maxillofac Surg* 72:61, 2014.
174. Fedele S, Porter SR, D'Aiuto F, et al: Nonexposed variant of bisphosphonate-associated osteonecrosis of the jaw: a case series. *Am J Med* 123:1060, 2010.
175. O'Ryan FS, Khoury S, Liao W, et al: Intravenous bisphosphonate-related osteonecrosis of the jaw: bone scintigraphy as an early indicator. *J Oral Maxillofac Surg* 67:1363, 2009.
176. Bedogni A, Fusco V, Agrillo A, et al: Learning from experience. Proposal of a refined definition and staging system for bisphosphonate-related osteonecrosis of the jaw (BRONJ). *Oral Dis* 18:621, 2012.
177. Schiodt M, Reibel J, Oturai P, et al: Comparison of nonexposed and exposed bisphosphonate-induced osteonecrosis of the jaws: a retrospective analysis from the Copenhagen cohort and a proposal for an updated classification system. *Oral Surg Oral Med Oral Pathol Oral Radiol* 117:204, 2014.
178. Kumar SK, Gorur A, Schaudinn C, et al: The role of microbial biofilms in osteonecrosis of the jaw associated with bisphosphonate therapy. *Curr Osteoporos Rep* 8:40, 2010.
179. Engroff SL, Kim DD: Treating bisphosphonate osteonecrosis of the jaws: is there a role for resection and vascularized reconstruction? *J Oral Maxillofac Surg* 65:2374, 2007.
180. Ferrari S, Bianchi B, Savi A, et al: Fibula free flap with endosseous implants for reconstructing a resected mandible in bisphosphonate osteonecrosis. *J Oral Maxillofac Surg* 66:999, 2008.
181. Seth R, Futran ND, Alam DS, et al: Outcomes of vascularized bone graft reconstruction of the mandible in bisphosphonate-related osteonecrosis of the jaws. *Laryngoscope* 120:2165, 2010.
182. Carlson ER, Fleisher KE, Ruggiero SL: Metastatic cancer identified in osteonecrosis specimens of the jaws in patients receiving intravenous bisphosphonate medications. *J Oral Maxillofac Surg* 71:2077, 2013.
183. United States. National Institutes of Health. Funding Opportunities and Notices Search Results. http://grants.nih.gov/grants/guide/search_results.htm?text_curr=osteonecrosis&scope=pa-rfa&year=active&sort=&Search.x=10&Search.y=8 Accessed February 10, 2014.